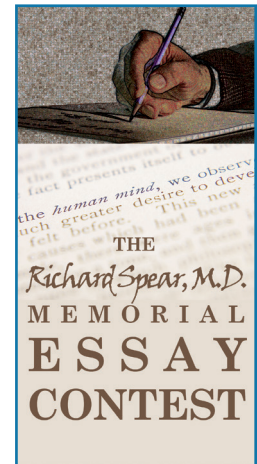



# HONORABLE MENTION

2014 RICHARD SPEAR, MD,  
MEMORIAL ESSAY CONTEST



## WARM AND DEAD?

Martin Huecker, MD



**P**ERRL. CTAB. RRR. Soft NTND. We write and dictate these acronyms so often they seem to lose meaning. Sometimes I wonder, did I actively elicit these signs? Did I actually listen to the lung sounds when I auscultated? Does what I found matter in the average patient? Is the physical exam dead?

With residents, I solemnly reflect upon the diminishing emphasis on physical exam in education. Sure the lungs sound clear, but we will likely obtain an X-ray to rule out pneumonia. No conjunctival icterus or yellow under the tongue, but still the bilirubin could be elevated. The Ottawa ankle rule obviated the radiograph in Mr. Smith, but he's not leaving without an X-ray. EMS transmits the STEMI ECG and I activate the Cath Lab before the patient even arrives. Does his physical exam matter?

Recently Dr. Sheri Welch wrote about the changing role of the physical exam. She noted studies from the 1970s and 1990s showing physical exam contributing to a patient's diagnosis 10 and 12 percent of the time. This was pre-everyone gets a CT- era. Welch notes the lack of physical exam findings incorporated into modern decision rules, the waning function of digital rectal exam in trauma, and the apparent lack of utility of the pelvic exam in first trimester bleeding. Another study suggests the pelvic exam may not change management in most female patients with abdominal pain.

But Dr. Welch does not devalue the physical exam. She echoes the appeal of Dr. Abraham Verghese that our patients want to be touched – they are expecting more examination than we are giving. This contrasts the discrediting looks I receive from patients when I explain that their abdominal exam suggests a CT is not indicated to rule out appendicitis. However, I agree that patients, often tacitly, rely on some physical exam for a sense of connection (and in 2014 they also want their money's worth).

With attention to these concerns, I decided to more closely observe the implications of physical examination in a week at work. What I found in the resuscitation of critically ill patients surprised me.

First patient: EMS brings her in short of breath. She is *sweating, hypertensive, tachypneic, speaks few-word sentences* and cannot give history. Physical exam is remarkable: *JVD, crackles in bases, peripheral edema, rapid pulse, frothy sputum*. Start BiPAP, Nitro drip, enalaprilat. We can order a BNP, troponin, chest X-ray, but these will not alter her course.

Next patient: He is vomiting coffee grounds and blood and cannot give history. On exam I feel a *pulse of 140. Patient looks pregnant, dilated veins on the abdomen, spider angiomas on chest. I palpate a firm, enlarged liver. He has dry mucous membranes. I sit him up and he turns pale, almost passes out.* I order FFP, pRBCs, octreotide, place a central line, call GI and the Intensivist. The patient needs resuscitation and endoscopy. I will obtain labs and a chest X-ray, but the physical exam gives me all the information I need.

Next one: EMS brings a woman who stopped speaking an hour ago. Family is on the way. The patient *will not look at me on her left side, so I walk around to her right. She makes eye contact but will not answer questions. Her face droops. Her right arm and leg are densely paretic.* I need a CT scan to rule out hemorrhage and labs to rule out coagulopathy. But my physical exam diagnosed a stroke and depending on contraindications, this patient may benefit from thrombolysis and could fully regain function.

Next patient: Young woman crying in pain, *distended abdomen, sweating, tachypneic, wants to push. Quick cervix check shows she is complete.* An ultrasound and fetal monitor would be nice, but this woman is in precipitous labor and no diagnostic tests are necessary to assist in decision-making.

One more: 20-year-old after motor vehicle collision. *Airway is*

# HONORABLE MENTION

2014 RICHARD SPEAR, MD, MEMORIAL ESSAY CONTEST

*occluded with secretions and patient not breathing, unconscious. I intubate. Breathing shows no breath sounds on the left and paradoxical motion of a section of crunchy ribs. Chest tube placed. Cardiovascular exam shows no pulse in the left foot. I notice the hip is internally rotated and the limb is shortened. After the perfunctory X-ray, I will reduce the hip dislocation. Next, his pupils: one is dilated, manual pulse check shows a heart rate of fifty. Bad news in the brain. The neurosurgeon still needs a head CT, but I have his attention (a facetious neurosurgical physical exam description: "Move your right arm, move your left arm, what's the CT show?"). We start mannitol and elevate his head en route to CT. I have diagnosed and temporized a severe head injury with increased intracranial pressure, respiratory failure, pneumothorax and flail chest all with physical exam alone.*

In these patients I made decisions and witnessed the effects of interventions based solely on physical exam findings. The most telling but rarely mentioned aspect of the physical exam, the general appearance, represents the culmination of years of our "practice" of medicine. Our art lies in this trained intuition inherent in the ability to walk into a room, immediately read the situation and begin caring for a patient.

Understanding the importance of a call to action, Dr. Welch proposes a five component physical exam to be done with *all* patients: tactile temperature, manual pulse, stethoscope on the chest, push on the belly, and a three-pronged neurological exam. Taking less than a few minutes, these gestures will leave the patient with an impression of completeness and satisfaction.

I propose a different call to action. Every workday we each recognize a physical exam finding that clinched a diagnosis or had some true impact on patient care. In critically ill patients, I am now convinced this will be easy. But in the monotonous day at the office completing well checks and pap smears, I insist we have not left Osler so far behind that we can simply autopilot every physical exam as a means to the end of "real" diagnostics. The physical exam just needs a little appreciation, resuscitation. Let's not pronounce it unless it is *warm* and dead.

## References

- Welch, Shari. Does a 10-Item Physical Exam Add Value to Patient Care? ACEP Now: Vol 33 – No 02 – February 2014.
- Hampton JR, Harrison MJ, Mitchell JR, et al. Relative contributions of history-taking, physical examination, and laboratory investigation to diagnosis and management of medical outpatients. *Br Med J.* 1975;2:486-489.
- Peterson MC, Holbrook JH, Von Hales D, et al. Contributions of the history, physical examination, and laboratory investigation in making medical diagnoses. *West J Med.* 1992;156:163-165.
- Aldous SJ, Richards MA, Cullen L, et al. A new improved accelerated diagnostic protocol safely identifies low-risk patients with chest pain in the emergency department. *Acad Emerg Med.* 2012;19:510-516.
- Esposito TJ, Ingraham A, Luchette FA, et al. Reasons to omit digital rectal exam in trauma patients: no fingers, no rectum, no useful additional information. *J Trauma.* 2005;59:1314-1319.
- Johnstone C. Vaginal examination does not improve diagnostic accuracy in early pregnancy bleeding. *Emerg Med Australasia.* 2013;25:219-222.
- Jeremy Brown, MD, Rita Fleming, MD, Jamie Aristzabel, MD, and Rocksolana Gishta, BA. Does Pelvic Exam in the Emergency Department Add Useful Information? *West J Emerg Med.* May 2011; 12(2): 208–212.
- Kravitz RL, Cope DW, Bhrany V, et al. Internal medicine patients' expectations for care during office visits. *J Gen Intern Med.* 1994;9:75-81.
- Bell RA, Kravitz RL, Thom D, et al. Unmet expectations for care and the patient-physician relationship. *J Gen Intern Med.* 2002;17:817-824. **LM**
- Note: Martin Huecker, MD, is a full time faculty member at the University of Louisville who practices Emergency Medicine with the University of Louisville Physicians group.*

The Richard Spear, MD, Memorial Essay Contest is a yearly writing competition hosted by the Greater Louisville Medical Society. Dr. Richard Spear, a respected Louisville general surgeon, passed away in 2007 and left GLMS a bequest to fund an annual essay contest. To view the Richard Spear, MD, Memorial Essay Contest archives, visit [www.glms.org/Default.aspx?PageID=530](http://www.glms.org/Default.aspx?PageID=530)